

MULTIMEDIA ARTICLE – Clinical Imaging

Papilla with Separate Bile and Pancreatic Duct Orifices

Surinder Singh Rana, Deepak Kumar Bhasin

Department of Gastroenterology, Post Graduate Institute of Medical Education and Research (PGIMER), Chandigarh, India

A 32-year-old male, a known case of alcohol related chronic non calcific pancreatitis, was referred to us for pancreatic endotherapy for relief of intractable abdominal pain. The cross sectional imaging studies had revealed an irregularly dilated main pancreatic duct. The examination of the major duodenal papilla revealed the presence of two separate orifices at endoscopic retrograde cholangiopancreatography (ERCP) (Image). The cranial orifice was located at 11-12 clock position whereas the caudal orifice was located at 4-5 clock position. The caudal orifice was selectively cannulated and the injection of the contrast revealed presence of an irregularly dilated main pancreatic duct. The cannula and the guide wire introduced through the caudal orifice selectively entered the pancreatic duct and did not come out through the cranial orifice. During ERCP, bile could be seen coming out of the cranial orifice, confirming it to be the orifice of common bile duct. Following selective cannulation of the main pancreatic duct, a 5-Fr stent was placed into the pancreatic duct. Following this, the patient had complete pain relief and is planned for further sessions of pancreatic endotherapy along with pancreatic sphincterotomy.

Separate orifices of the common bile duct and pancreatic duct have been rarely reported [1, 2]. Normally, the common bile duct and the pancreatic duct join together at the level of the duodenum to form the ampulla of Vater. Complete non union of the bile and pancreatic duct can give rise to separate orifices of these two ducts. This rare anatomic variation has been reported to be associated with an increased risk of common bile duct stones owing to biliary stasis [3].

Conflict of interest The authors have no potential conflicts of interest

References

1. Silvis SE, Vennes JA, Dreyer M. Variation in the normal duodenal papilla. *Gastrointest Endosc* 1983; 29:132-133 [PMID; 6852473]

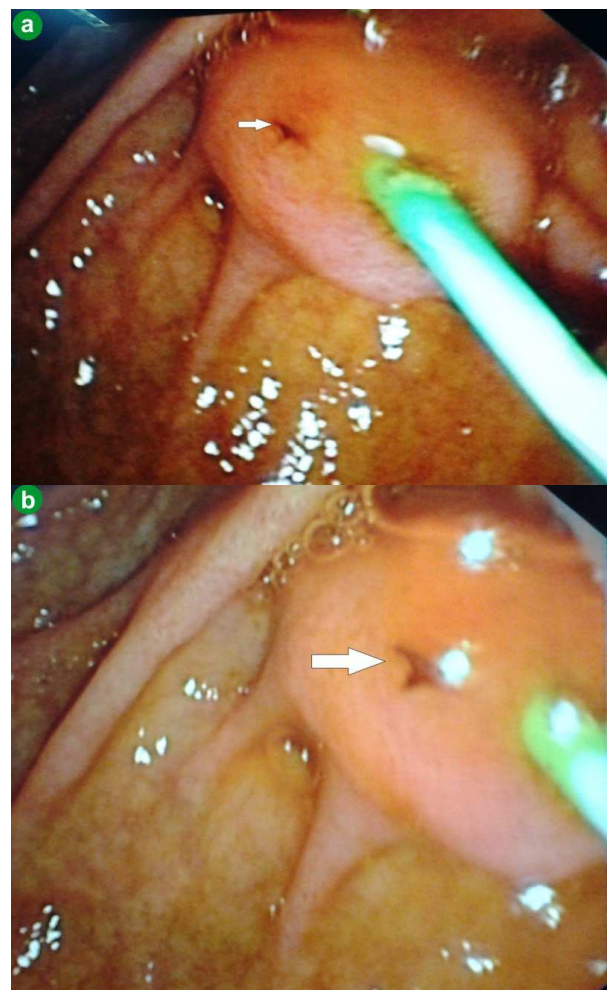


Image. Papilla with separate bile duct (arrow) and pancreatic duct orifice (green stent).

Received February 25th, 2013 – Accepted March 10th, 2013

Key words Cholangiopancreatography, Endoscopic Retrograde; Pancreatitis, Alcoholic; Pancreatitis, Chronic; Stents

Correspondence Surinder Singh Rana

Department of Gastroenterology; Postgraduate Institute of Medical Education and Research (PGIMER); Sector 12; Chandigarh; India 160012

Phone: +91-172.274.9123; Fax: +91-172.274.4401

E-mail: drsurinderrana@yahoo.co.in; sonalisurinder@yahoo.co.in

2. Francis J, Kadakia S. Anomalous double orifice of a single major papilla of Vater. *Gastrointest Endosc* 1994; 40:324-325 [PMID: 7926559]

3. Kubota K, Fujisawa T, Abe Y, Inamori M, Kirikoshi H, Saito S, et al. Clinical significance of the duodenal papilla in patients with separate orifices for the bile and pancreatic ducts. *J Gastroenterol.* 2007 ;42:70-8. [PMID: 17322996]
