

CASE REPORT

Peripancreatic Castleman Disease

Nazif Erkan¹, Mehmet Yıldırım¹, Elif Selek², Şehnaz Sayhan²

¹Department of 2nd Surgery and ²Department of Pathology, SSK Izmir Training Hospital.
Izmir, Turkey

ABSTRACT

Context Castleman disease or giant lymph node hyperplasia is a rare disorder of the lymphoid tissue, usually occurring in the mediastinum. We report a case of localized peripancreatic plasma cell type Castleman disease, which is an unusual site.

Case report A 45-year-old woman with a history of mild epigastric pain radiating to the back for the previous year was admitted and her physical examination was normal. A raised erythrocyte sedimentation rate, C-reactive protein and hypergammaglobulinemia were found. Abdominal ultrasonography and magnetic resonance imaging demonstrated a homogeneously hypoechoic solid mass having a smooth-surface, 6 cm in diameter, located between the head of the pancreas, the lower margin of the antrum and the left lobe of the liver. The mass was totally excised surgically with repair of the pancreas capsule. Histopathological examination of the tumor showed plasma-cell type Castleman disease.

Conclusion Clinicians should be aware that Castleman disease may involve peripancreatic tissue which leads to difficulties in arriving at a differential diagnosis. Surgical excision is both a diagnostic and a curative method for management of the disease.

INTRODUCTION

Castleman disease is a relatively rare disorder characterized by benign proliferation of lymphoid tissue and was first described by Castleman and Towne in 1954 [1]. The disease may occur anywhere along the lymphatic chain, but the mediastinum is the most common location. It usually presents as a localized soft tissue mass in the neck or the mediastinum, but it rarely manifests clinically in a multicentric form or in the retroperitoneum [2, 3, 4]. We report herein a case of localized peripancreatic Castleman disease.

CASE REPORT

A 45-year-old woman with a history of mild epigastric pain radiating to back for the previous year was admitted to the hospital for further investigation. In her past history, she had been treated with insulin for type-2 diabetes mellitus. She had no family history of malignancy or inherited disease. Her physical examination was normal except for a mild tenderness in the epigastrium. In laboratory tests, an elevated erythrocyte sedimentation rate, C-reactive protein and hypergammaglobulinemia were found. There was no serological indication of active HIV infection. Upper gastrointestinal endoscopy showed mild antral gastritis. Abdominal ultrasonography demonstrated a

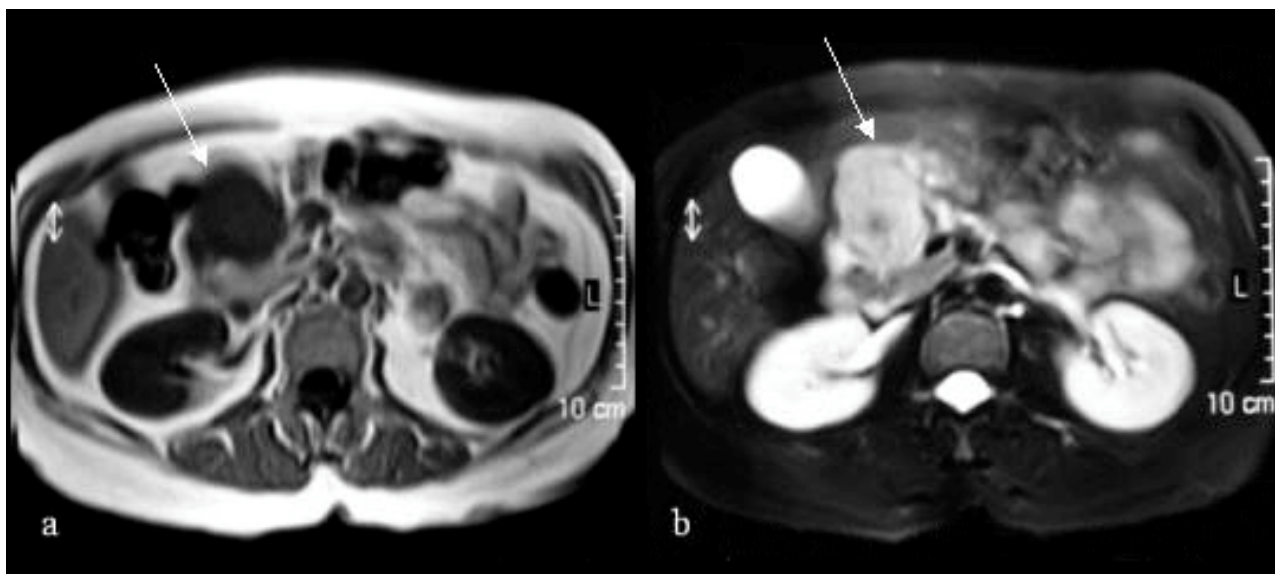


Figure 1. Abdominal magnetic resonance imaging shows a well-capsulated, isodense, solid mass (**a.** arrows, T1-weighted) and heterogeneous signal characteristics, that is, a central hypodense area within the mass (**b.** T2-weighted).

homogeneously hypoechoic solid mass having a smooth-surface, 6 cm in diameter, located between the head of the pancreas, the lower margin of the antrum and the left lobe of the liver. A small bowel series was reported as within normal limits. Abdominal magnetic resonance (MR) imaging confirmed an exophytic, well-capsulated, isodense solid mass, 42x48x52 mm in size, located on the inferomedial side of the antrum of the stomach, over the anterior of the 3rd portion of the duodenum and the head of the pancreas. MR imaging also showed a hypodense area at the center of the lesion (Figure 1). Exploratory laparotomy revealed a smooth, fleshy solid mass measuring 7x5x5 cm, located at the anterior surface of the head of the pancreas which was densely adherent to the 3rd portion of the duodenum and the greater curvature of the antrum of the stomach. The mass was totally excised with repair of the pancreas capsule. Grossly the mass was round and well-circumscribed with a solid grey cut surface showing a nodular and granular pattern (Figure 2). Histopathological examination of the tumor showed plasma cell type Castleman disease: large follicles with germinal centers and loss of sinusoids in a mass of lymphoid tissue. The follicles showed vascular proliferation and prominent plasma cell proliferation in the

interfollicular region (Figure 3). The postoperative clinical course was uneventful and the patient has been free of disease for one year.

DISCUSSION

Castleman and Towne [1] described a disease characterized by a benign mediastinal mass

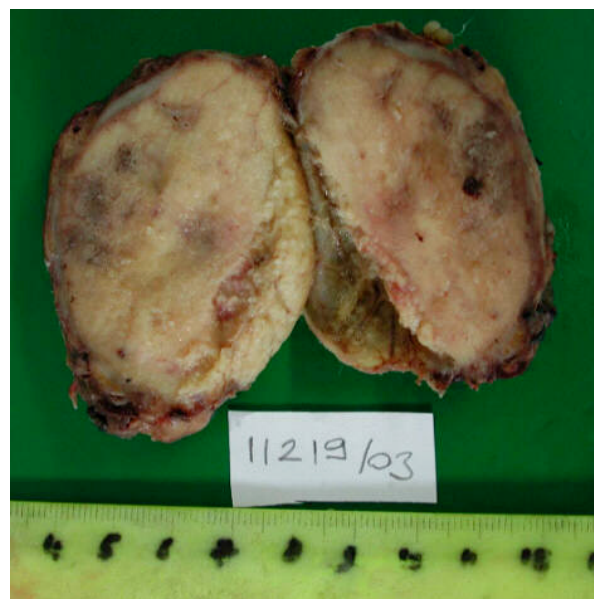


Figure 2. Macroscopy of the excised tumor demonstrates a well-circumscribed round mass with a solid grey cut surface showing a nodular and granular pattern

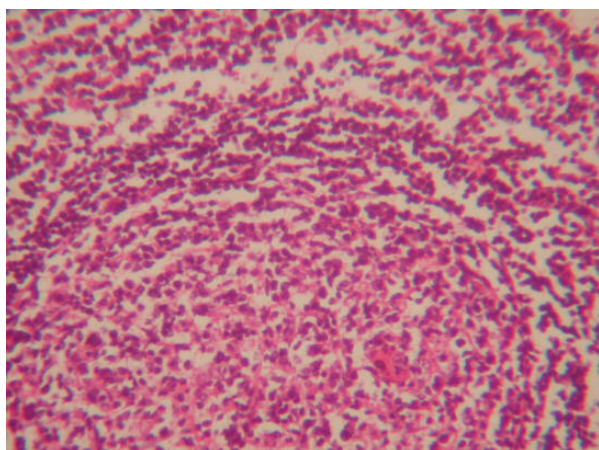


Figure 3. Histopathological examination of the tumor shows plasma-cell type Castleman disease: large follicles with germinal centers and loss of sinusoids in a mass of lymphoid tissue. with prominent plasma cell proliferation in the interfollicular region. (H&E x100)

resembling a thymoma. Although popularly known as Castleman disease, this disease entity has many synonyms including giant lymph node hyperplasia, lymph node hamartoma, angiofollicular mediastinal lymph node hyperplasia and angiomatous lymphoid hyperplasia [5].

Little is known about the cause of this disorder. However, the bulk of evidence points toward faulty immunoregulation which results in the excessive proliferation of B lymphocytes and plasma cells in lymphoid organs [6]. Most of the lesions are located in the thorax but extrathoracic involvement including neck, axilla, mesentery, pelvis, pancreas, adrenal and retroperitoneum has also been reported [4, 7].

There are two major histologic variants: a) the hyaline-vascular type, which is more frequent, is characterized by small hyaline-vascular follicles and interfollicular capillary proliferation, and b) the plasma cell type, which is characterized by large follicles with intervening sheets of plasma cells [4, 5]. Clinically, the hyaline-vascular type is usually asymptomatic whereas the less common plasma cell variant is sometimes associated with systemic manifestations such as fever, anemia, weight loss, night sweats, and polyclonal hypergammaglobulinemia [2, 3]. Currently, Castleman disease is classified into two clinicopathologically distinct subgroups:

localized and disseminated Castleman disease. The localized disease typically has a benign course and the disseminated disease is usually malignant [2, 3, 4]. The multicentric variety with severe systemic manifestations and poor prognosis is frequently associated with polyneuropathy,, organomegaly, endocrinopathy, M protein and skin change (POEMS) syndrome, Kaposi sarcoma, and AIDS [2, 6]. In our case, the patient had localized plasma cell type Castleman disease with signs, symptoms and laboratory findings which correlated with the literature.

Ultrasonography, CT and MR imaging have been proven to be helpful in diagnosing retroperitoneal tumors; however, Castleman disease is radiographically and operatively indistinguishable from other diseases. The ultrasonographic picture is similar to that seen in lymphoma: a uniform hypoechoic mass with enhanced through-transmission [8]. CT consistently shows solid density and homogeneously enhanced masses with or without calcification. The usual appearance of this entity on CT is that of a non-specific homogenous mass which ranges from hypo- to isodense in relation to the liver on non-contrasted studies. Dense enhancement immediately after the infusion of iodinated material is observed. Generally, the tumors of Castleman disease are described nearly isointense to muscle in signal intensity on T1-weighted MR imaging, with heterogeneous signal characteristics within the mass on T2-weighted MR imaging [7, 9]. The distribution of abdominal lymphadenopathy is non-specific and not helpful in the differentiation from other nodal diseases. In our patient, US and MR imaging showed almost typical characteristics.

The radiological differential diagnosis includes various neoplastic (lymphoma), inflammatory (tuberculosis or sarcoidosis) and other miscellaneous retroperitoneal tumors. From the radiological and clinical points of view, disseminated Castleman disease is indistinguishable from that of lymphoma. Therefore, a biopsy of an enlarged lymph node is mandatory for the differential diagnosis [5, 7, 9].

Surgical excision is the treatment of choice for localized disease [3, 4]. In cases with multicentric disease, the treatment has not been definitively established and the clinical course of that type of disease can be chronic, with remission and exacerbation requiring continuous therapy or malignant, rapidly progressive and fatal. Multicentric systemic treatment with steroids or chemotherapy or both resulted in varying success [3, 6]. In our case, a complete surgical excision was made and no evidence of tumor recurrence has been detected in the one year since surgery.

As a conclusion, clinicians should be aware that Castleman disease may involve peripancreatic tissues which leads to difficulties in arriving at a differential diagnosis. Surgical excision is both the diagnostic and the curative method for management of the disease.

Received August 17th, 2004 - Accepted
September 14th, 2004

Keywords Diagnosis, Differential;
Diagnostic Imaging; Giant Lymph Node
Hyperplasia; Pancreas; Pancreatic Diseases;
Surgical Procedures, Operative

Correspondence

Nazif Erkan
14 Sok. No:18/14
35350 Üçkuyular
Izmir
Turkey
Phone: +90-532.348.3107
Fax: +90-232.261.4444
E-mail: naziferkan2002@hotmail.com

References

1. Castleman B, Towne VW. Case reports of Massachusetts General Hospital; weekly clinicopathological exercises; founded by Richard C. Cabot. Case 40011. N Engl J Med 1954; 250:26-30. [PMID 13194083]
2. Bowne WB, Lewis JJ, Filippa DA, Niesvizky R, Brooks AD, Burt ME, et al. The management of unicentric and multicentric Castleman disease: a report of 16 cases and a review of the literature. Cancer 1999; 85:706-17. [PMID 10091744]
3. Herrada J, Cabanillas F, Rice L, Manning J, Pugh W. The clinical behaviour of localized and multicentric Castleman disease. Ann Intern Med 1998; 128:657-62. [PMID 9537940]
4. Keller AR, Hochholzer L, Castleman B. Hyaline vascular and plasma cell types of giant lymph node hyperplasia of the mediastinum and other locations. Cancer 1972; 29:670-83. [PMID 4551306]
5. Walter JF, Rottenberg RW, Cannon WB, Sheridan LA, Pizzimenti J, Orr JT. Giant mediastinal lymph node hyperplasia (Castleman's disease): angiographic and clinical features. AJR Am J Roentgenol 1978; 130:447-50. [PMID 415545]
6. Peterson BA, Frizzera G. Multicentric Castleman's disease. Semin Oncol 1993; 20:636-47. [PMID 8296200]
7. Debatin JF, Spritzer CE, Dunnick NR. Castleman disease of adrenal glands. MR imaging features. AJR Am J Roentgenol 1991; 157:781-3. [PMID 1892035]
8. Barki Y, Shadked G, Levy I. Mesenteric Castleman disease: sonographic diagnosis. J Clin Ultrasound 1992; 20:486-8. [PMID 1324956]
9. Johkoh T, Muller NL, Ichikado K, Nishimoto N, Yoshizaki K, Honda O, et al. Intrathoracic multicentric Castleman disease: CT findings in 12 patients. Radiology 1998; 209:477-81. [PMID 9807577]